

OUR PHYSICIANS

Gregg D. Alzate, M.D.
 John A. Amberg, M.D.
 Howard M. Bear, M.D.
 Scott Boles, M.D.
 Bruce L. Bower, M.D.
 Patrick H. Carey, M.D.
 William D. Carter, M.D.
 Norman C. Chen, M.D.
 Nathaniel A. Chuang, M.D.
 Shanoë Cutts, M.D.
 John J. Dente, M.D.
 Christopher E. Dory, M.D.
 Jerry R. Dwek, M.D.
 Darryl K. Evora, M.D.
 Robert P. Flynn, M.D.
 Lawrence E. Goldberger, M.D.
 Jonathan M. Gurney, M.D.
 John P. Hauschildt, M.D.
 Keith E. Kortman, M.D.
 Peter G. Kruk, M.D.
 Russell N. Low, M.D.
 James W. Lyon, M.D.
 John H. Naheedy, M.D.
 Clinton R. Nichols, M.D.
 Walter L. Olsen, M.D.
 Neeraj (Nick) Panchal, M.D.
 Julie Pondron, M.D.
 Robert J. Prager, M.D.
 Michael L. Puckett, M.D.
 Howard R. Schiffman, M.D.
 Christopher P. Sebrechts, M.D.
 Melvin O. Senac, Jr., M.D.
 Joel S. Sigeti, M.D.
 Daniel N. Vinocur, M.D.
 Victor L. Woo, M.D.
 Robert C. Yacullo, M.D.



*Russell N. Low, M.D. -
 Medical Director
 Sharp and Children's
 MRI Center*

Breast MR Imaging - New Recommendations from the American Cancer Society

“MR imaging of the breast detects small cancers that can be missed on mammography and physical examination.”

Recognizing the value of breast MRI the American Cancer Society now recommends that certain women undergo routine annual breast MRI combined with mammography starting when they are 30 years old. These women include those at high risk for breast cancer.

1. Women with a genetic mutation that increases their risk of breast cancer. These breast cancer genes are known as BRCA1 and BRCA2.
2. Women who have not yet been tested but have a family member with the BRCA1 or BRCA2 gene mutation.
3. Women who have a strong family history of breast cancer. Examples include:
 - a. Two close family members with breast cancer – mother, daughter, sister
 - b. Single close family member who developed breast cancer before 50 years of age.

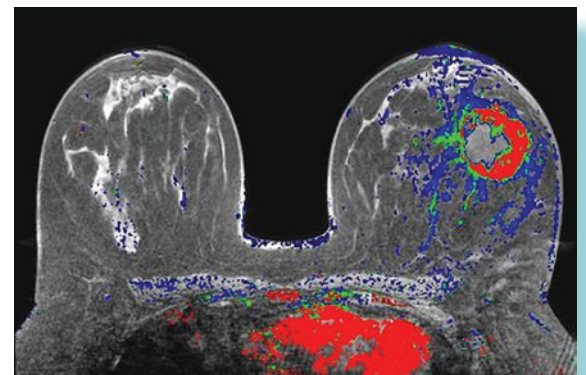
4. Women who had radiation to the chest for Hodgkin's disease between the ages of 10-30 years.

Recent studies have also found that women with newly diagnosed breast cancer should have a breast MRI to look for cancer in other sites or in the opposite breast. These studies have found that in 3% of women the breast MRI will show tumor in the other breast that is not detected on mammography. Discovering these other tumors earlier allows them to be treated improving a woman's chances for cure.

Other situations in which Breast MRI can be used include:

1. Women with breast implants that can limit the effectiveness of mammography to detect cancers.
2. Women with a palpable breast lump that is not seen on mammography or breast ultrasound.
3. Following lumpectomy breast MRI can be used to detect any remaining tumor if there is a question about the completeness of the surgical resection.

At Sharp and Children's MRI Center we have extensive experience performing and interpreting breast MR exams. Over the last several years we have performed breast MRI



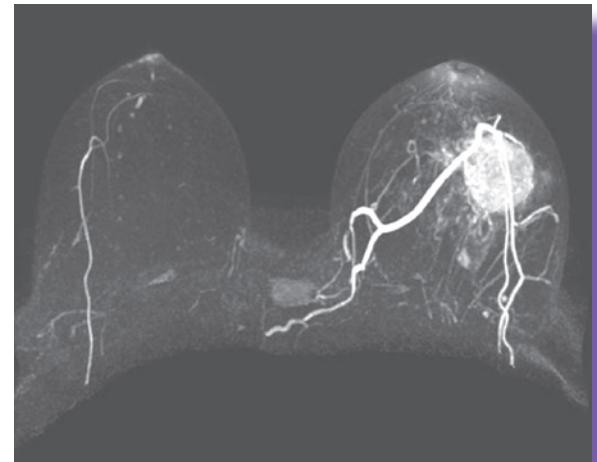
On the CAD Sciences breast MRI the red and green portions indicate the active tumor. Blue is normal breast tissue. Spread of the tumor to other parts of the breast or to the lymph nodes is best seen on these colorized images.

Breast MR Imaging *(continued from page 1)*

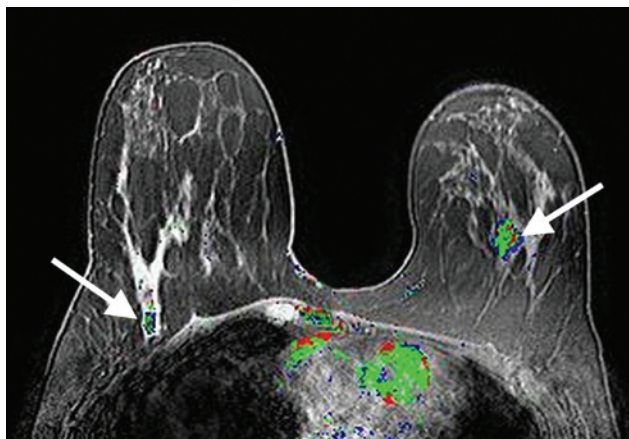
for thousands of San Diego women. Our nurses and MR technologists are very highly trained and will perform your study in a caring and patient friendly setting.

Breast MRI is safe and does not use ionizing radiation. MRI uses magnetic fields and radio waves to make very highly detailed images of the breast. Unlike mammography where the technologist compresses the breast tissue and then takes two pictures, breast MRI generates hundreds of detailed images of each breast so that all of the breast tissue is thoroughly examined. Breast cancers light up with contrast material making them easy to detect on MRI. The entire breast MR examination takes about 30 minutes to complete.

After the breast MRI is performed all of the images are examined by a board certified radiologist. A *CAD Sciences Breast MRI Workstation* assists the radiologist detect cancers by coloring suspicious breast tumors. We have found the CAD Sciences images for breast MRI are extremely important to detect small cancers that might otherwise be missed.



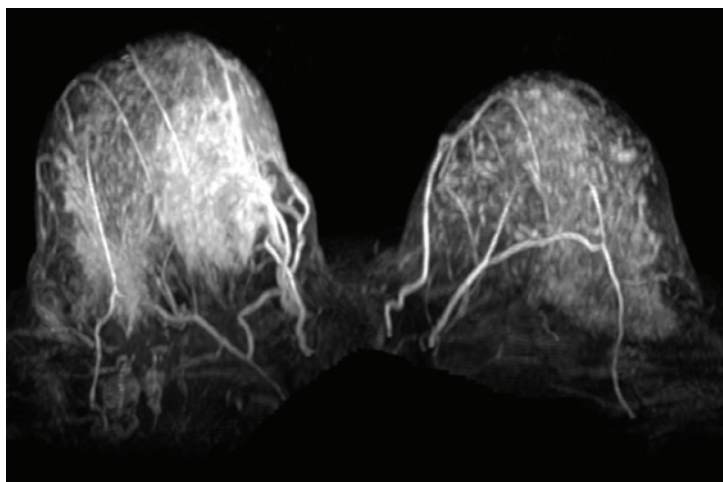
Breast MRI shows a large cancer in the left breast.



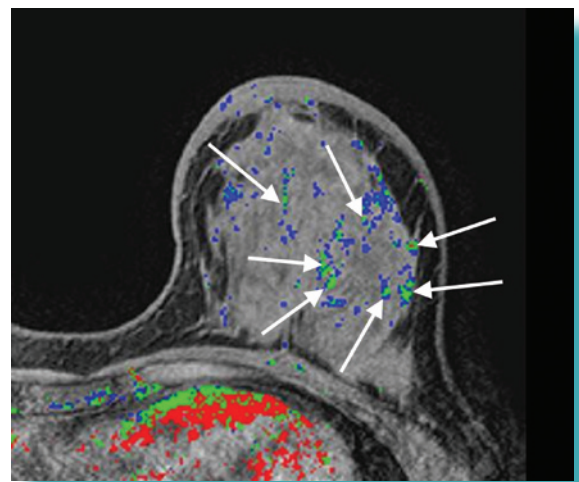
Patient with a normal mammogram had a lump under her arm. The breast MRI shows cancer in both breasts.

This year there will be almost 200,000 women diagnosed with breast cancer in the United States. The good news is that this is a potentially curable cancer if it is found early before it has spread to other areas of the body. Finding a breast cancer as early as possible improves the likelihood that treatment will be successful.

Breast MRI is clearly the most sensitive imaging test to diagnose breast cancer. It should always be used in conjunction with annual mammography and breast self examination. At Sharp and Children's MRI we are pleased to offer comprehensive breast MRI and hope that we can be of service to you in the future. Please call anytime for more information or to schedule an appointment (858) 939-4560.



This is a breast MRI of a woman with a large right breast mass. Her mammogram and breast ultrasound had been normal for over 1 year. She could feel a mass and eventually had a breast MRI performed.



Patient with diffuse multicentric breast cancer. The CAD Sciences colorized images help to detect these small cancers.